

THE IMPACT OF ALUMINUM CHLORIDE SUB-ACUTE EXPOSURE ON THE REPRODUCTIVE SYSTEM OF MALE RATS

*Boudou F,^{1,2} Bendahmane-Salmi M,^{1,2} Benabderrahmane M¹,
Benalia A,^{1,2} Beghdadli B.²

¹Department of Biology, Faculty of Natural and Life Sciences, DjillaliLiabes University of Sidi-Bel-Abbes, Sidi-Bel-Abbes, Algeria.

²Research Laboratory of Environment and Health (RLEH), Faculty of Medicine, Sidi-Bel-Abbes, Algeria.

*Author for Correspondence: farouk.boudou@univ-sba.dz

ABSTRACT

In order to elucidate the Aluminum chloride (AlCl₃) male reproductive toxicity mechanisms, twelve mature male rats were divided into 2 groups (n=6). The first group received orally AlCl₃ (34 mg/kg body weight) while rats from the second group, without any treatment, served as control. After 30 days of experimentation, AlCl₃ exposure showed a significant decrease in body weight. Semen analysis showed a significant decrease in sperm count ($4.58 \pm 0.65 \times 10^6$ cells/mL), sperm viability (61.53 ± 23.63 %), and a significant increase in morphological abnormalities (26.11 ± 17.84 %), with a predominance of head (14.54 ± 8.38 %) and flagellum defects (14.22 ± 20.60 %). Sperm DNA integrity analysis revealed a high percentage of fragmented DNA (69.05 ± 4.36 %). Hormones analysis showed a significant decrease in serum testosterone (0.31 ± 0.26 ng/ml) and an increase in luteinizing hormone (LH) (0.56 ± 0.47 mUI/mL) levels, whereas, no significant changes were observed in follicle stimulating hormone (FSH) level. A significant elevation in testicular Malondialdehyde (0.16 ± 0.015 μM/g) and catalase activity levels (69 ± 14.29 mM H₂O₂/min/mg) were also observed. Degeneration of testicular epithelial and interstitial tissues was observed, with an increase in apoptotic cells, and an inflammatory state revealed by leukocytic infiltration in epididymal tissue. We suggest that sub-acute exposure to AlCl₃ affects the Leydig cells which results in the decrease in testosterone level and an increase in LH Level as a response to the interruption of testosterone negative feedback. Low testosterone level affects the spermatogenesis and causes the appearance of an inflammatory reaction in response to the increase rate of apoptosis in the epididymal epithelial tissue.

Keywords: Aluminum, Testis, Epididymis, Sperm, Hormones.

INTRODUCTION

Aluminum (Al) is the third most abundant element in the earth's crust and is omnipresent in our environment, including our food (Klein 2019). It is readily available for human ingestion through the use of food additives, gastric antacid drugs, buffered aspirin, astringents, nasal sprays, and antiperspirants; from drinking water; from automobile exhaust and tobacco smoke; and from using aluminum foil, aluminum cookware, cans, ceramics, and fireworks (Baby et al. 2010). It has for a long time been considered on an indifferent element from a toxicological point of view (Yousef 2004). However, in the 70s the nephrological community was alerted for the first time to the occurrence of an epidemic human pathology induced by acute aluminum poisoning in patients undergoing hemodialysis (Seidowsky et al. 2018). Then the neurotoxicity

of aluminum was clearly stated. Aluminum is known as a neurotoxin that can cause certain diseases such as Alzheimer's disease, dialysis dementia, Parkinsonism, and amyotrophic lateral sclerosis (Kawahara et al. 2011). Al accumulation in tissues and organs results in their dysfunction and toxicity (Pandey et al. 2013). Studies carried out to determine the mechanisms of Al-induced neurodegeneration and its relationship to Alzheimer's disease indicate that Al toxicity is mediated through reactive oxygen species (ROS) production. ROS induce instability of the cell membrane (Kim et al. 2006), destruction of DNA structures (Takabe et al. 2001), and DNA damages (Kawanishi et al. 2001). They also induce toxicity in humans and other living organisms by interfering with the activity of vital enzymes (Machida et al. 2010). Although the knowledge of Al toxicity has markedly improved in recent years; however, information concerning the mechanism of male

reproductive toxicity *in vitro* of this element is still very limited. Cheraghi et al. (2017) reported that it can be concluded that Al causes reproductive dysfunction by creating oxidative damage. Al cytotoxicity may be mediated by free radicals derived from this element and its capability to induce apoptosis through a wide variety of mechanisms including production of ROS, LPO, cell membrane damage, diminished activity of alkaline phosphatase and cAMP reduction in various tissues (Pandey et al. 2013; Savory et al. 2003). Chronic AlCl₃ exposure caused deterioration in sperm motility and viability, enhancement of free radicals and alterations in enzymes activities. Aluminum was shown to exert a pro-oxidant activity and promotes biological oxidation both *in vitro* and *in vivo* (Exley 2004). Therefore, the aim of the current study is to elucidate the Aluminum chloride sub-acute exposure mechanisms of male reproductive toxicity *in vivo* by a biochemical, serological, cytological and histological approaches.

MATERIALS AND METHODS

Experimental design

Experiments were carried out on twelve Wistar mature males, aged of 3 months and weighing 191.63 ± 38.03 g. The animals were housed in room with a 12/12-hour light/ dark cycle, at $22 \pm 2^\circ\text{C}$ and had access to *ad libitum* to water and special rodent pellet diet (15% proteins). Rats were randomly allocated into 2 groups, with 6 rats in each group. The first group received, by oral route, water-containing AlCl₃ at the dose of 34 mg/kg body weight (b.w.) according to Moselhy et al. (2012), and control group without any treatment. All the experiment lasted for 30 days during which animal weight was measured every week.

Specimens and Analytical methods

At the end of the experiment, animals were euthanized using diethyl ether in a large desiccator (Kim et al. 2018). Testis and epididymis were carefully removed, separated from their fat tissues, rinsed with saline solution, and weighed in order to calculate the corresponding index (organ weight/body weight ratio) according to Qin et al. (2013). Blood was collected from the inferior cava vena for the

determination of testosterone, luteinizing hormone (LH), and follicle stimulating hormone (FSH) levels by mean of immunoassay commercial kits (VIDAS Assays, BIOMERIEUX). Semen samples were collected by maceration of the epididymis in physiological saline solution (0.9%) at 35-37 °C for 15 min to form the sperm suspension. Semen characteristics, including sperm count and percent viability were evaluated according to Wang (2002) and Soleimanzadeh et al. (2013) respectively. The sperm abnormalities were classified in order of importance as follows: head, middle piece and flagella. As soon as an anomaly is identified, the spermatozoa are directly classified in the "abnormal" (Al-Ani et al. 2009). Evaluation of testicular oxidative stress markers: malondialdehyde (MDA) and catalase activity (CAT) were measured in testicular homogenate as described by Azad et al. (2019). Testicular and epididymal histological study was performed according to standard techniques, after fixation in fixative solution (formalin 1/10), paraffin embedding, and staining with hematoxylin-eosin (Ghosh et al. 2019).

Statistical analysis

The mean \pm SD values were calculated for each group to determine the significance of intergroup difference. Each parameter was analyzed separately using two ways analysis of variance (ANOVA). To find the difference between the groups Bonferroni t-test was used. *P* values <0.05 were considered to be significant.

RESULTS

Effect of Aluminum on body weight and organ index

Table 1 showed that before embarking on the experiment, the two groups had no significant difference in body weight ($p>0.05$). From the second week, administration of AlCl₃ caused a significant decrease ($p<0.001$) in body weight of rats as compared to the controls. However, no significant changes were observed in both testis and epididymis index between the two groups.

Table 1. Effect of AlCl₃ exposure on body weight and testicular index

Groups	Body weight (g)					Testis index	Epididymis index
	W ₀	W ₁	W ₂	W ₃	W ₄		
AlCl ₃	202.3±45.22	209.8±27.91	229.8±32.60	247.5±30.40	226.33±24.65	0.58±0.06	0.31±0.03
CONTROL	189.5±6.40	217.5±3.50	257±1.43	275.5±9.21	275±1.40	0.59±0.08	0.40±0.09

Al: AlCl₃ exposed group; C: a control group with no treatment; W: week. Data are expressed as means ± SD (n=6). The comparison of means between groups was performed by the Bonferroni t-test of Student after analysis of variance (ANOVA): **p* < 0.05, ***p* < 0.01, ****p* < 0.001.

Effect of Aluminum on semen parameters

Exposure to AlCl₃ significantly affected all sperm parameters studied compared to control group. Table 2 showed a significant decrease (*p* < 0.001) in sperm count (4.58±0.65

×10⁶ /ml) and sperm viability (61.53±23.60 %), with a significant increase (*p* < 0.001) in DNA fragmented spermatozooids (69.05±4.36 %) and abnormal sperm rate (26.11±17.84 %).

Table 2. Effect of AlCl₃ on semen parameters

Groups	Sperm count (10 ⁶ /ml)	Parameters		
		Morphology (abnormal %)	Viability (%)	DNA fragmentation (%)
AlCl ₃	4.58±0.65 ***	26.11±17.84 **	61.53±23.60 ***	69.05±4.36 ***
CONTROL	11.52±0.77	16.67±1.53	76.33±6.51	39.33±6.44

Al: AlCl₃ exposed group; C: a control group with no treatment. Data are expressed as means ± SD (n=6). The comparison of means between groups was performed by the Bonferroni t-test of Student after analysis of variance (ANOVA): **p* < 0.05, ***p* < 0.01, ****p* < 0.001.

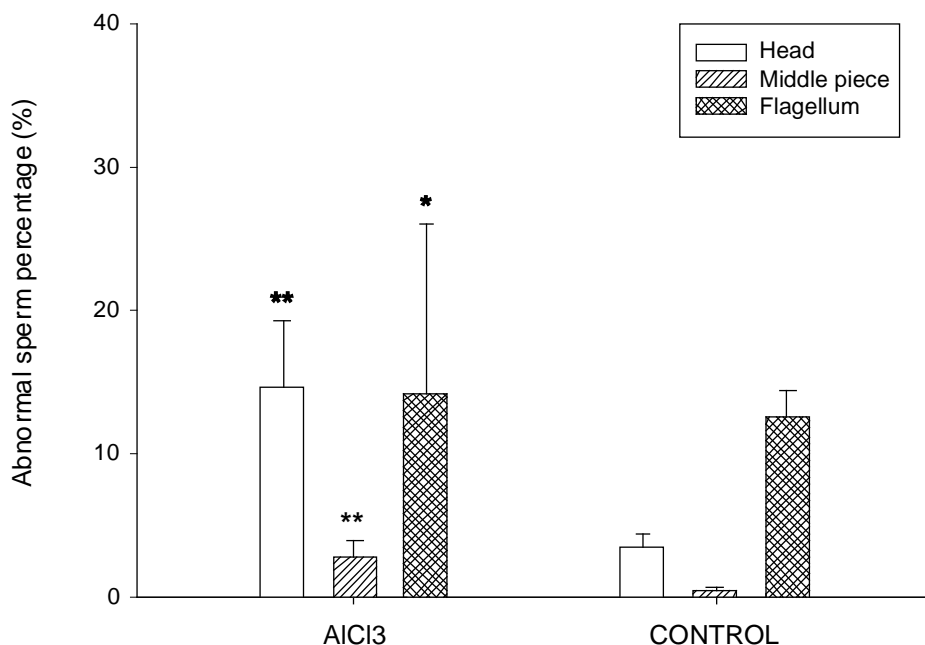


Figure 1. Evaluation of abnormal sperm rate according to the type and localization of anomalies.

Data are expressed as means ± SD (n=6). The comparison of means between groups was performed by the Bonferroni t-test of Student after analysis of variance (ANOVA): **p* < 0.05, ***p* < 0.01, ****p* < 0.001.

Effect of AlCl₃ on hormones levels

Results of the current study showed that administration of AlCl₃ significantly decreased ($p < 0.05$) serum testosterone and luteinizing

hormone levels as compared to the corresponding control values; whereas, no significant changes were observed in the follicle stimulating hormone (FSH) level (Figure 2).

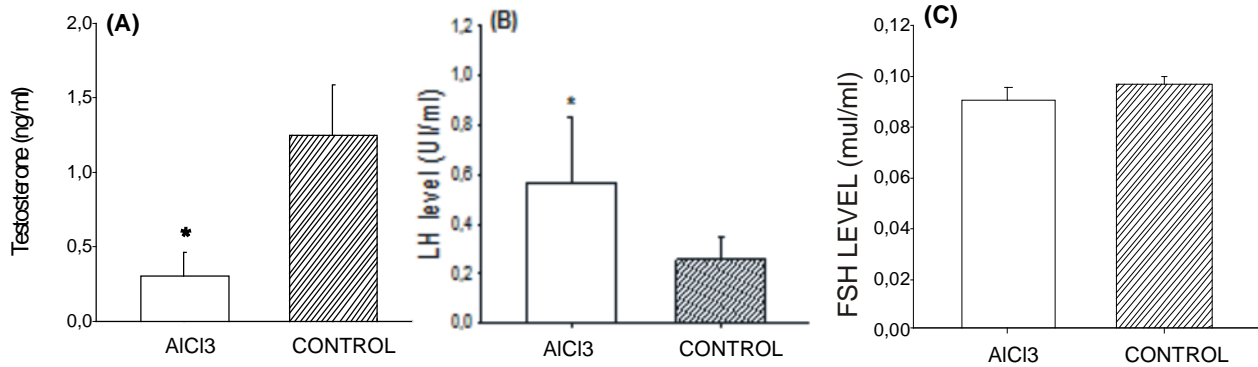


Figure 2. Evaluation of hormones levels in different experimental groups.

A: Serum testosterone level; B: serum luteinizing hormone (LH) level; C: follicle stimulating hormone (FSH) level. Data are expressed as means \pm SD (n=6). The comparison of means between groups was performed by the Bonferroni t-test of Student after analysis of variance (ANOVA): * $p < 0.05$, ** $p < 0.01$, *** $p < 0.001$.

Evaluation of testicular oxidative stress markers

In this study, two complementary tests were used to assess the ability of AlCl₃ sub-acute exposure to induce testicular oxidative stress:

determination of Malondialdehyde (MDA) and Catalase activity (CAT). Figure 3 showed a significant increase ($p < 0.05$) in MDA level and CAT activity in Al exposed group compared to the controls.

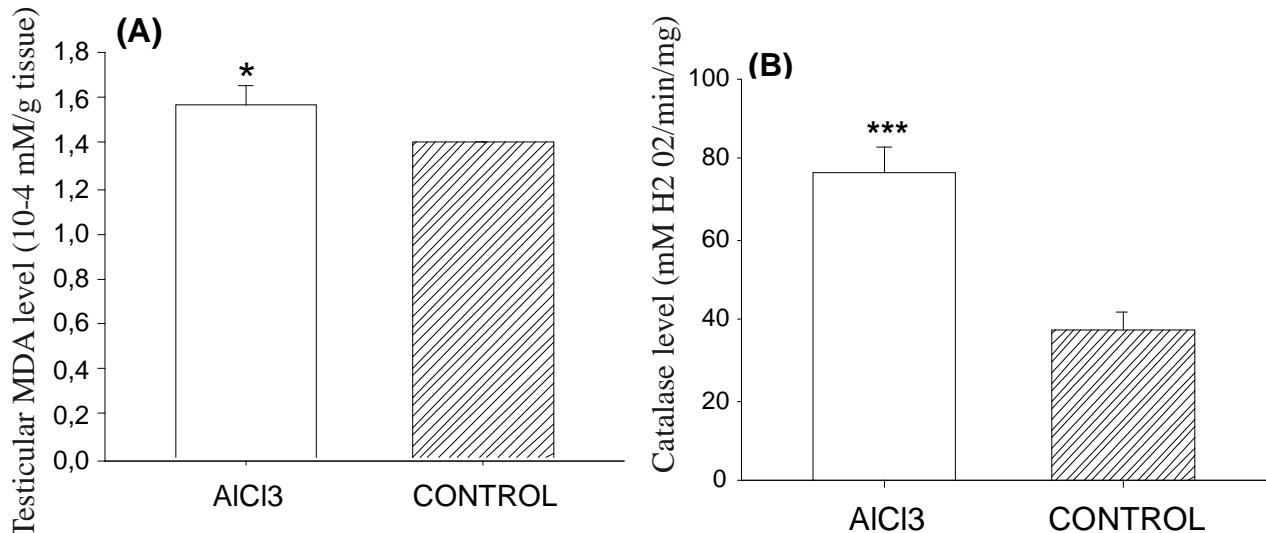


Figure 3. Evaluation of Testicular oxidative stress markers.

A: Testicular Malondialdehyde (MDA) level. B: Testicular Catalase activity level. Data are expressed as means \pm SD (n=6). The comparison of means between groups was performed by the Bonferroni t-test of Student after analysis of variance (ANOVA): * $p < 0.05$, ** $p < 0.01$, *** $p < 0.001$.

Histopathological Study

Histological study reveals a normal architecture in the testicles structure of the control group (Figures 4-A) showing seminiferous tubules richly populated with a healthy appearance. All stages of the spermatogenic cell lines such as spermatogonia, spermatocyte, spermatids, and spermatozoa, even Sertoli cells could be identified in the seminiferous tubules. Lumen could easily be delineated in almost all the tubules and the majority of them were filled by mature spermatozoa. While the observation of histological sections of the AlCl₃-exposed group (Figure 4-B) shows that all these stages are affected. Among the disturbances reported: degeneration of the seminiferous tubules with

disorganization of germinal epithelium, low sperm count and the presence of some exfoliated cells in the lumen, degeneration of interstitial tissue with large interstitial spaces and lack of Leydig cells around basement membranes. In epididymal tissue, the microscopic examination showed a normal architecture in the control group (Figure 5-A) with a pseudostratified ciliated columnar epithelium surrounded by connective tissue and smooth muscles and a lumen filled with spermatozoa. However AlCl₃-exposed rats showed an epididymal tissue with a disorganized epithelium, an elevation of apoptotic cells due to the low level of testosterone and a proliferation of lymphocytes which indicates an inflammatory state (Figure 5-B).

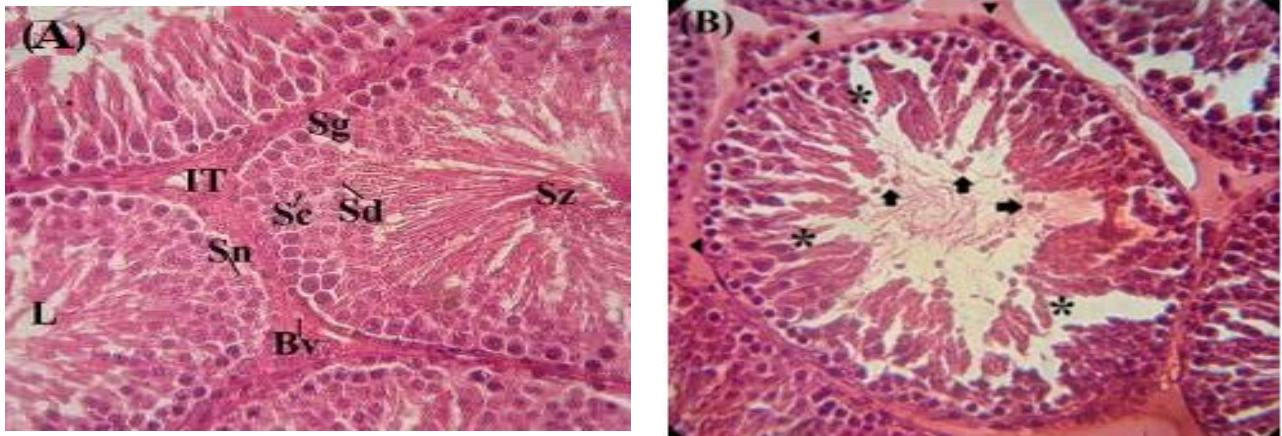


Figure 4. Microscopic observation of Haematoxylin stained testicular sections.

A: Control rats sections showing normal progression of spermatogenesis from spermatogonia (Sg) to spermatozoa (Sz) via spermatocytes (Sc) and spermatids (Sd). Interstitial tissue (IT) formed by Leydig cells and blood vessels (Bv). The Sertoli cell nucleus (Sn) and the lumen of the seminiferous tube (L) filled of spermatozoa. **B:** AlCl₃-exposed rat testis Showing disorganization of germinal epithelium (asterisks), lack of Leydig cells, and degeneration of interstitial tissue (arrowheads) with some exfoliated cells in the lumen (arrows) (x40).

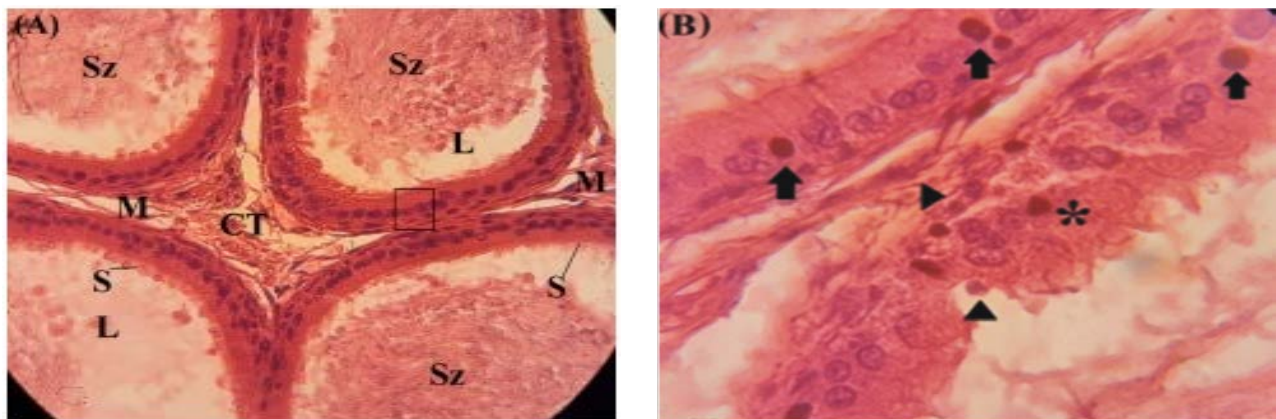


Figure 5. Microscopic observation of Haematoxylin stained epididymal sections. **A:** Control rats sections showing epididymal tubes formed by a pseudostratified ciliated columnar epithelium (black box) surrounded by connective tissue (CT) and smooth muscles (M). The stereocilia (S) clearly visible and a lumen (L) filled with sperm (Sz) (x40). **B:** AlCl₃-exposed rat epididymal tissue showing disorganized epithelium (asterisk), apoptotic cells (arrowheads), and a leukocytic infiltration (arrows) (x100).

DISCUSSION

Results of the current study revealed that sub-acute exposure to 34 mg/kg b.w. of aluminum chloride during 30 days led to many physiological and histological dysfunctions, namely a body gain loss, decrease of sperm quality, hormonal disorders and histological abnormalities. A significant decrease in body weight was recorded from the second week of exposition to AlCl₃. But no significant decrease was shown in organ index. These results are in agreement with those of Balgoon (2019) who showed that administration of 10 mg/kg AlCl₃ during 8 weeks caused a significant ($p < 0.001$) reduction in rats weight gain (7.67 ± 2.87 g) compared to the control (92.00 ± 18.61 g). Another study conducted by Lahouel et al. (2020), showed that a weekly aluminum intraperitoneal dose of 60mg/kg during 6 to 12 weeks showed intense changes over time in body and brain weight, they suggested that this decreases could be attributed to the interaction of Al with the hormonal status and /or protein synthesis. Moreover, semen analysis showed a significant decreased in sperm count, viability, and an increase in sperm abnormal morphology percent in rats exposed to Al compared to controls. These results are in accordance with those obtained by Abdul-Rasoul et al. (2009) who revealed that a daily administration of Aluminum chloride with two doses 40 and 80 mg/kg body weight induced a significant reduction in sperm concentration and percentage of live sperm, associated with a significant increase in the percentage of abnormal sperm. Another research conducted by Martinez et al. (2017) found that exposure to aluminum for 60 days at human dietary levels (1.5, 8.3 and 100 mg/kg b.w./day) affects the sperm quality in rats by decreasing sperm count, sperm motility, and sperm morphology, with an increase in oxidative stress and inflammation in reproductive organs. They found also that a low concentration of Al ($3.35 \mu\text{g/g}$) in testes is sufficient to impair spermatogenesis. Miska-Schramm et al. (2017) by using the Bank Vole (*Myodesglareolus*) as a rodent model indicated that AlCl₃, at a dose of 3 and 200 mg/L, impairs adult reproductive abilities by decreasing the quality and quantity of sperm cells and by causing morphologically abnormal development of the gonads. Also, Guo

et al. (2005) indicated that aluminum exposure leads to an increase in nitric oxide (NO) products which were responsible for Al-induced reproductive toxicity. Zhu et al. (2014) suggested that sub-chronic AlCl₃ disorders the balance of trace element and decreases the spermatogenesis and testicular enzyme activities which have adverse effects on the testicular function in male rats. We also find that AlCl₃ affected sperm DNA integrity revealed by increasing the percentage of sperm fragmented DNA. A number of reports discuss DNA fragmentation in sperm cells exposed to PbCl₄ *in-vitro* Gomes et al. (2015). Metals can cause male infertility through affection of spermatogenesis and sperm quality. Strong evidences confirm that male infertility in metal-exposed humans is mediated via various mechanisms such as production of reactive oxygen species (ROS) Jamalan et al. (2016). On the other hand, the results of the current study indicated that the administration of AlCl₃ significantly decreased serum testosterone and increased LH levels compared to control rats. These findings are consistent with those of Sun et al. (2011), who noticed a significant decrease in the levels of testosterone, follicle-stimulating hormone (FSH) and luteinizing hormone (LH) after 120 days of exposition to three doses (64.18, 128.36 and 256.72 mg/kg) of aluminum and explain that Al-exposure interferes with androgen receptor expressions in testes. Another work indicated that AlCl₃ caused a significant decrease of FSH, LH, and testosterone, and caused the development of oligospermia and exfoliated tubules in the testis (Al-Eisa et al. 2017). Knowing that, testosterone hormone is released from the Leydig cells by stimulation of LH, its reduction results in the decline of serum testosterone concentration. Furthermore, our study showed that Al exposure caused an elevation in the MDA and CAT levels as compared to control group. Our finding confirmed those of Akayet al. (2016) who concluded that sub-chronic exposure to Al (75 mg/kg/ day during 30 days) lead to a significant decrease on antioxidant enzymes such as SOD and GPx, and a significant increase in MDA levels compared to control group. This imbalance between the antioxidant system and oxidants leads to an oxidative stress which has a

destructive effect on the testis. The work of Afolabi et al. (2018) on Aluminum-phosphide, indicated that oral administration of Al (1.15mg/kg) during 30 days resulted in a significant increase in testicular MDA and oxidized protein levels with a decrease in antioxidant enzymes such as SOD, CAT and GPx followed by a significant reduction in non-enzymatic antioxidants. While, the observation of histological sections of the AlCl₃ exposed group shows the degeneration of the seminiferous tubules and depletion of sperm in the seminiferous lumen, with large interstitial spaces and lack of cells Lydig around the basement of membranes. These results are following those obtained by Moselhy et al. (2012) who demonstrated after histopathological examination of rats testis exposed to a daily dose (34 mg/kg) of AlCl₃ during 60 days, revealed degenerative changes in seminiferous tubules with necrosed spermatogenic cells. Besides, our result showed that Al caused in epididymal tissue a disorganization of epithelium, and elevation of apoptotic cells due to the low level of testosterone and an inflammatory state revealed by the leukocytic infiltration. These results agree with those of Mesole et al. (2020) who showed that exposure to AlCl₃ resulted in a significant (p < 0.01) elevation in the levels of nitric oxide and 8-hydroxy-2-deoxyguanosine (8-OHdG), enhanced the activity of caspase-3, increased the level of pro apoptotic protein Bax and reduced the levels of anti-apoptotic protein Bcl-2, and significantly (p < 0.01) reduced the levels of SOD and GPx. While, The histopathological examination of mice exposed to AlCl₃ (2 mg/kg b.w) during 3 months showed degeneration of spermatogenic cell in the somniferous tubules of testes with formation of spermatid giant cells inside the lumen with interstitial inflammation (Manal et al. 2017).

CONCLUSION

The present study demonstrated that sub-acute exposure to AlCl₃ affects the testicular Leydig cells which results in the decrease in testosterone level and an increase in LH Level as a response to the interruption of the negative feedback of this hormone. Low testosterone level affects also the spermatogenesis and causes

the appearance of an inflammatory reaction in response to the increase rate of apoptosis in the epididymal epithelial tissue.

Conflicts of Interest

Authors have declared that they have no competing interest.

REFERENCES

- Abdul-Rasoul EM, Hassan NH, Al-Mallah KH. (2009). Effect of aluminium chloride on sexual efficiency in adult male rats. 22 (4):27-44.
- Afolab OK, Wusu AD, Ugbaja R, Fatoki JO. (2018). Aluminium phosphide-induced testicular toxicity through oxidative stress in Wistar rats: Ameliorative role of hesperidin. Toxicology Research and Application. 2: 1-11. 2397847318812794.
- Akay C, Erdem O, Aydin A, Eken A, Sayal A. (2016). Oxidative effects of aluminum on testes and erythrocytes in rats. Trace Elements and Electrolytes. 33 (4):155-161.
- Al-Ani IM, Al-Khfaji IN, Fakhridin MB, Mangalo HH, Al-Obaidi SR. (2009). The effect of lead exposure of mice during pregnancy on the morphology of epididymal and testicular spermatozoa of their offspring. IIUM Medical Journal Malaysia. 8 (1):11-16.
- Al-Eisa RA, Al-Nahari HA. (2017). The attenuating effect of royal jelly on hormonal parameters in aluminum chloride (AlCl₃) intoxicated rats." International Journal of Pharmaceutical Research & Allied Sciences. 6 (2) :70-85.
- Azad F, Nejati V, Shalizar-Jalali A, Najafi G, Rahmani F. (2019). Antioxidant and anti-apoptotic effects of royal jelly against nicotine-induced testicular injury in mice. Environmental toxicology. 34 (6):708-718.
- Baby J, Raj JS, Biby ET, Sankarganesh P, Jeevitha MV, Ajisha SU, Rajan SS. (2010). Toxic effect of heavy metals on aquatic environment. International Journal of Biological and Chemical Sciences. 4(4): 939-952.
- Balagoon MJ. (2019). Assessment of the protective effect of Lepidium sativum against aluminum-induced liver and kidney effects in albino rat. BioMed Research International. 2019:1-9.
- Cheraghi E, Golkar A, Roshanaei K, Alani B. (2017). Aluminium-induced oxidative stress, apoptosis and alterations in testicular tissue and sperm quality in Wistar rats: ameliorative effects of curcumin. International journal of fertility &

- sterility. 11 (3):166-175.
- Exley C. (2004). The pro-oxidant activity of aluminum. *Free Radical Biology and Medicine*. 36 (3):380-387.
- Ghosh D, Mondal S, Ramakrishna K. (2019). Acute and sub-acute (30-day) toxicity studies of *Aegialitis rotundifolia* Roxb., leaves extract in Wistar rats: safety assessment of a rare mangrove traditionally utilized as pain antidote. *Clinical Phytoscience*. 5 (1):5-13.
- Gomes M, Gonçalves A, Rocha E, Sá R, Alves A, Silva J, Barros A, Pereira ML, Sousa M. (2015). Effect of in vitro exposure to lead chloride on semen quality and sperm DNA fragmentation. *Zygote*. 23 (3):384-393.
- Guo CH, Lin CY, Yeh MS, Hsu GSW. (2005). Aluminum-induced suppression of testosterone through nitric oxide production in male mice. *Environmental toxicology and pharmacology*. 19(1):33-40.
- Kim JG, Chandrasekaran K, Morgan W. (2006). Mitochondrial dysfunction, persistently elevated levels of reactive oxygen species and radiation-induced genomic instability: a review. *Mutagenesis*. 21 (6):361-367.
- Jamalan M, Ghaffari MA, Hoseinzadeh P, Hashemitabar M, Zeinali M. (2016). Human sperm quality and metal toxicants: protective effects of some flavonoids on male reproductive function. *International journal of fertility & sterility*. 10 (2):215-223.
- Kawahara M, Kato-Negishi M. (2011). Link between aluminum and the pathogenesis of Alzheimer's disease: the integration of the aluminum and amyloid cascade hypotheses. *International journal of Alzheimer's disease*. 2011:1-17.
- Kawanishi S, Hiraku Y, Oikawa S. (2001). Mechanism of guanine-specific DNA damage by oxidative stress and its role in carcinogenesis and aging. *Mutation Research/Reviews in Mutation Research*. 488 (1):65-76.
- Kim EJ, Jang M, Choi JH, Park KS, Cho IH. (2018). An improved dehydroepiandrosterone-induced rat model of polycystic ovary syndrome (PCOS): Post-pubertal improve PCOS's features. *Frontiers in Endocrinology*. 9:735-741.
- Klein GL. (2019). Aluminum toxicity to bone: A multisystem effect? Osteoporosis and sarcopenia. 5 (1):2-5.
- Lahouel Z, Kharoubi O, Boussadia A, Bekkouche Z, Aoues A. (2020). Effect of Aluminium and Aqueous extract of *Rosmarinus officinalis* on rat Brain: Impact on Neurobehavioral and Histological study. *Journal of Drug Delivery and Therapeutics*. 10 (4):179-187.
- Machida K, McNamara G, Cheng KTH, Huang J, Wang CH, Comai L, Lai MM. (2010). Hepatitis C virus inhibits DNA damage repair through reactive oxygen and nitrogen species and by interfering with the ATM-NBS1/Mre11/Rad50 DNA repair pathway in monocytes and hepatocytes. *The Journal of Immunology*. 185 (11):6985-6998.
- Manal MS, Marwa FA, Doaa SM. (2017). The protective role of DMSA and vitamin E & selenium on aluminum induced neuro and reproductive toxicity in male rats. *Animal Health Research Journal*. 5 (1):52-70.
- Martinez CS, Escobar AG, Uranga-Ocio JA, Peçanha FM, Vassallo DV, Exley C, Marta M, Wiggers GA. (2017). Aluminum exposure for 60 days at human dietary levels impairs spermatogenesis and sperm quality in rats. *Reproductive Toxicology*. 73:128-141.
- Mesole SB, Alfred OO, Yusuf UA, Lukubi L, Ndhlovu D. (2020). Apoptotic Inducement of Neuronal Cells by Aluminium Chloride and the Neuroprotective Effect of Eugenol in Wistar Rats. *Oxidative Medicine and Cellular Longevity*. 2020:1-7.
- Moselhy WA, Helmy NA, Abdel-Halim BR, Nabil TM, Abdel-Hamid MI. (2012). Role of ginger against the reproductive toxicity of aluminium chloride in albino male rats. *Reproduction in domestic animals*. 47 (2):335-343.
- Pandey G, Jain GC. (2013). A review on toxic effects of aluminium exposure on male reproductive system and probable mechanisms of toxicity. *International journal of toxicology and applied pharmacology*. 3 (3):48-57.
- Qin D, Wen Z, Nie Y, Yao G. (2013). Effect of cichorium glandulosum extracts on CCl4-induced hepatic fibrosis. *Iranian Red Crescent Medical Journal*. 15 (12):1-8.
- Savory J, Herman MM, Ghribi O. (2003). Intracellular mechanisms underlying aluminum-induced apoptosis in rabbit brain. *Journal of inorganic biochemistry*. 97 (1):151-154.
- Seidowsky A, Dupuis E, Drueke T, Dard S, Massy ZA, Canaud B. (2018). Intoxication aluminique en hémodialyse chronique. Un diagnostic rarement évoqué de nos jours. Illustration par un cas clinique et revue de la littérature. *Néphrologie & Thérapeutique*. 14 (1):35-41.
- Soleimanzadeh A, Saberivand A. (2013). Effect of curcumin on rat sperm morphology after the

- freeze-thawing process. In Veterinary Research Forum. Faculty of Veterinary Medicine, Urmia University, Urmia, Iran. Vol. 4, No. 3, p. 185-189.
- Sun H, Hu C, Jia L, Zhu Y, Zhao H, Shao B, Li Y. (2011). Effects of aluminum exposure on serum sex hormones and androgen receptor expression in male rats. *Biological trace element research*. 144 (1-3):1050-1058.
- Takabe W, Niki E, Uchida K, Yamada S, Satoh K, Noguchi N. (2001). Oxidative stress promotes the development of transformation: involvement of a potent mutagenic lipid peroxidation product, acrolein. *Carcinogenesis*. 22 (6):935-941.
- Wang Y. (2002). Epididymal sperm count. *Current protocols in toxicology*. 14 (1):16.6. 1-16.6. 5.
- Yousef MI. (2004). Aluminium-induced changes in hemato-biochemical parameters, lipid peroxidation and enzyme activities of male rabbits: protective role of ascorbic acid. *Toxicology*. 199 (1):47-57.
- Zhu YZ, Sun H, Fu Y, Wang J, Song M, Li M, Miao LG. (2014). Effects of sub-chronic aluminum chloride on spermatogenesis and testicular enzymatic activity in male rats. *Life sciences*. 102 (1):36-40.